



PATIENT

Lucy Smith

SPECIES

Feline

BREED

DSH

SEX

FS

AGE

14 y

WEIGHT

3 kg

INTERPRETED BY

Keith Blass, DVM, MS,
DACVIM (Cardiology)

IMAGING PERFORMED BY

Dr. Brian Barnes

HOSPITAL NAME

Westview VH

REFERRING VET

Dr. Barnes

INVOICE

DATE

11/11/25

PRESENTING CLINICAL SIGNS

Recheck HOCM. Receiving atenolol 6.25mg SID.

ECHOCARDIOGRAPHIC FINDINGS

2D, M-mode, and Doppler study. This exam is compared to the one performed 5/6/25

Left atrial size is normal. There is mild hypertrophy of the interventricular septum. Left ventricular posterior wall thickness is normal. Left ventricular internal dimensions are normal. Left ventricular systolic function is hyperdynamic. There is systolic anterior motion of the mitral valve leaflets creating mild dynamic obstruction to flow in the left ventricular outflow tract, with mild secondary mitral regurgitation. The aorta and aortic valve are normal. Right atrial and right ventricular dimensions are normal. The tricuspid valve appears normal, though trace tricuspid regurgitation is present. The pulmonary artery and pulmonic valve appear normal, though trace pulmonic insufficiency is present. No shunting lesions are visualized. No pericardial effusion or cardiac masses are seen.

ECG during echo: Sinus rhythm

LA/Ao – 1.06

IVSd – 6.4 mm (prev. 6.4 mm)

LVPWd – 5.0 mm (prev. 5.0 mm)

LVIDd – 10.4 mm (prev. 11.1 mm)

LVIDs – 3.7 mm (prev. 4.1 mm)

FS – 64% (prev. 63%)

LVOT – 2.48 m/s (prev. 2.33 m/s)

RVOT – 1.44 m/s (prev. 1.58 m/s)

ASSESSMENT/RECOMMENDATIONS

Hypertrophic obstructive cardiomyopathy (HOCM)

This examination demonstrates no progression of Lucy's cardiac disease over the past 6 months. As such, her risk for the development of congestive heart failure, thromboembolic disease, and/or arrhythmia formation still appears to be fairly low.

No change in therapy is recommended at this time.

A recheck echocardiogram is recommended in 9 months. Thoracic radiographs are recommended if Lucy experiences respiratory clinical signs.



PATIENT

Lucy Smith

SPECIES

Feline

BREED

DSH

SEX

FS

AGE

14 y

WEIGHT

3 kg

INTERPRETED BY

Keith Blass, DVM, MS,
DACVIM (Cardiology)

IMAGING PERFORMED BY

Dr. Brian Barnes

HOSPITAL NAME

Westview VH

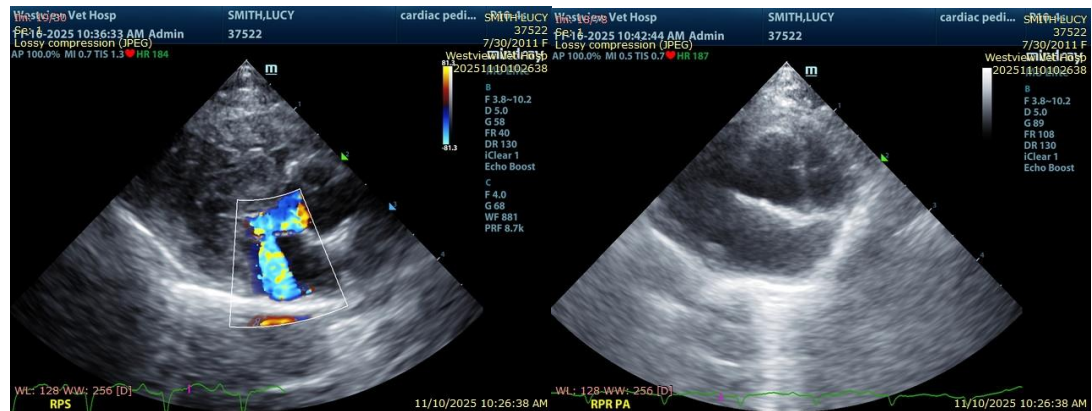
REFERRING VET

Dr. Barnes

INVOICE

DATE

11/11/25



The information and recommendations provided are based on the images presented by the referring veterinarian/sonographer. No evaluation can be communicated regarding pathology that was not visible in the image/video clips provided.

Thank you for this referral. If the clinical or image interpretation does not parallel your findings or if I can be of any further assistance please contact me.

Keith Blass, DVM, MS, DACVIM (Cardiology)

info@SonoPath.com